



RESENTING CLINICAL SIGNS

History: Grade 2/6 murmur, gallop sound. Pre-anesthetic evaluation.

DATE

4/13/23

ECHOCARDIOGRAPHIC FINDINGS

2D, M-mode, and Doppler study.

PERFORMED BY:

Val Shumskaya

INTERPRETED BY

Keith Blass, DVM,
MS, DACVIM
(Cardiology)

Left atrial size is normal. The mitral valve appears normal, though trace mitral regurgitation is present. Left ventricular wall thickness is normal. Left ventricular internal dimensions are normal. Left ventricular systolic function is hyperdynamic. The aorta and aortic valve are normal. There is moderate right atrial and mild right ventricular dilation. The tricuspid valve appears normal, though trace tricuspid regurgitation is present. The pulmonary artery and pulmonic valve appear normal, though trace pulmonic insufficiency is present. No shunting lesions are visualized. No pericardial effusion or cardiac masses are seen.

LA/Ao – 1.46
IVSd – 4.4 mm
LVPWd – 4.4 mm
LVIDd – 13.6 mm
LVIDs – 4.9 mm
FS – 64%
LVOT – 0.95 m/s
RVOT – 1.21 m/s

PATIENT

Isis Quinn

SPECIES

Feline

ASSESSMENT/RECOMMENDATIONS

Normal echocardiogram

BREED

DSH

This examination demonstrates no evidence of structural heart disease, as trace regurgitation of blood across Isis's tricuspid and pulmonic valves can be considered normal physiologic variants. As such, no reason for her murmur or gallop sound is seen, and consideration should be given to other possible causes, such as systemic hypertension and hyperthyroidism.

SEX

FS

Isis's cardiovascular risk for general anesthesia appears to be low based on this exam, and there are no contraindications to the use of any specific anesthetic agents.

No therapy is recommended based on this exam.

AGE

13 y

A recheck echocardiogram is recommended if the characteristics of Isis's murmur change, or if other new physical exam and/or clinical abnormalities suggestive of the presence of cardiac dysfunction develop.

WEIGHT

13 lb

HOSPITAL NAME

HoHoKus Vet

REFERRING VET

Dr. Scott



DATE

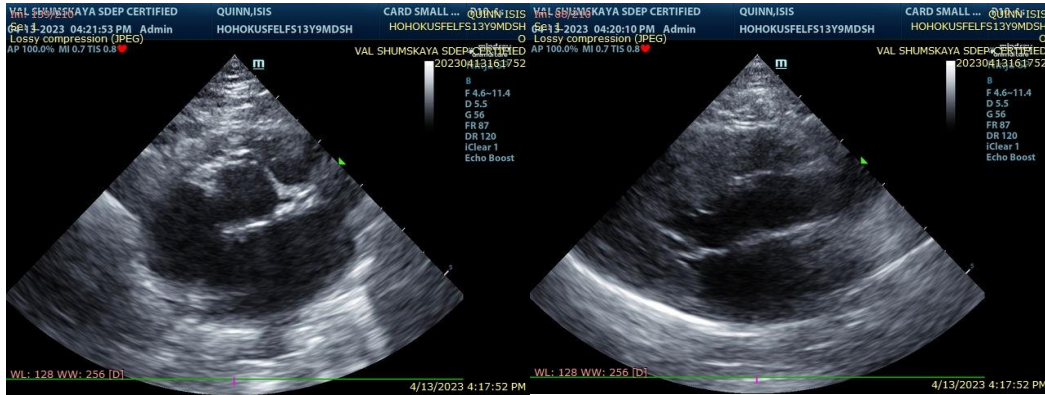
4/13/23

PERFORMED BY:

Val Shumskaya

INTERPRETED BY

Keith Blass, DVM,
MS, DACVIM
(Cardiology)



The information and recommendations provided are based on the images presented by the referring veterinarian. No evaluation can be communicated regarding pathology that was not visible in the image/video clips provided.

PATIENT

Isis Quinn

SPECIES

Feline

BREED

DSH

SEX

FS

AGE

13 y

WEIGHT

13 lb

HOSPITAL NAME

HoHoKus Vet

REFERRING VET

Dr. Scott

Thank you for this referral. If the clinical or image interpretation does not parallel your findings or if I can be of any further assistance please contact me.

Keith Blass, DVM, MS, DACVIM (Cardiology)
KeithBlass@gmail.com
631-804-5754